

## Case Report

# The treatment effect of the atopic dermatitis by electrolytic-reduction ion water lotion

Tetsuo Shu<sup>1,\*</sup>, Masahiro Okajima<sup>2</sup>, Yuko Wada<sup>2</sup>, Ken-ichi Shimokawa<sup>2</sup>, Fumiyoshi Ishii<sup>2,\*\*</sup>

<sup>1</sup> Daikanyama Clinic of Cosmetic Surgery, Shibuya-ku, Tokyo, Japan;

<sup>2</sup> Department of Pharmaceutical Sciences, Meiji Pharmaceutical University, Tokyo, Japan.

**ABSTRACT:** A female in her late 20s was diagnosed with systemic atopic dermatitis in another hospital 5 years earlier and treated by steroid ointment application to the affected areas and oral steroid administration. She visited our hospital due to the aggravation of dermatitis symptoms over the entire face from 1 week earlier. Lesions were present on the face, chest, neck, and bilateral upper limbs, and, in particular, facial dermatitis was extensive. A diagnosis of systemic atopic dermatitis complicated by infection was made. As oral drugs, a herbal medicine and steroid/antihistamine combination tablet were used. As topical drugs, an steroid/antibiotic combination ointment and vitamin E/A ointment were applied. In addition, injections for the treatment of allergic disease were used, and acidic electrolyzed water and an electrolytic-reduction ion water (ERI) lotion were topically applied. While receiving the two types of oral drug, she received a subcutaneous injection once a week and the application of acidic electrolyzed water, ERI lotion, steroid/antibiotic combination ointment, and vitamin E/A ointment to the lesions twice a day. One week after the initiation of treatment, redness and swelling decreased. After 1 month, the swelling further decreased, but the redness remained. After 1.5 months, the redness further decreased, showing a favorable course. Three months after the initiation of treatment, slight redness remained, but the skin color was almost normal. This patient showed the improvement of skin redness and swelling and an almost normal skin state without pigmented scars. These results suggest the effectiveness of complex therapy consisting of a herbal medicine and steroid/antihistamine combination drug as oral drugs and

an steroid/antibiotic combination ointment and vitamin E/A ointment as topical drugs, injections for allergic disease, and acidic electrolyzed water and ERI lotion for disinfection and skin care.

**Keywords:** Electrolytic-reduction ion water, atopic dermatitis, acidic electrolyzed water, infectious disease

### 1. Introduction

Atopic dermatitis is caused by multiple factors including a genetic predisposition, and there is no drug therapy for the complete resolution of the disease itself. However, even when the condition becomes chronic, if symptoms are controlled by appropriate treatment, and the controlled state is maintained, spontaneous remission can be expected. Therefore, palliative therapy is performed in principle (1). Atopic dermatitis is accompanied by skin dryness and barrier function abnormality, and non-specific stimulatory responses and specific allergic responses are involved in its development. In many patients with an atopic predisposition, skin inflammation becomes chronic, and is accompanied by pruritus, and scratching behavior induces bacterial, fungal, or viral skin infection, aggravating symptoms, and the disease becomes chronic. The genetic factors predisposing to atopic dermatitis include diseases such as bronchial asthma, allergic rhinitis, conjunctivitis, or atopic dermatitis in the family or a past history and a predisposition for excessive IgE antibody production (2). Atopic dermatitis is mainly treated by the topical application of steroids or tacrolimus ointments of immunosuppressive agents to inflammatory skin areas, skin care with moisturizing and protective agents, and the oral administration of antihistamine and antiallergic agents for itching as adjunctive therapy to alleviate symptoms (3).

When an aqueous solution containing electrolytes such as NaCl or KCl-MgCl<sub>2</sub> is electrolyzed using an electrolysis cell with a diaphragm (septum or

\*Dr. Tetsuo Shu passed away.

\*\*Address correspondence to:

Dr. Fumiyoshi Ishii, Department of Pharmaceutical Sciences, Meiji Pharmaceutical University, 2-522-1 Noshio, Kiyose, Tokyo 204-8588, Japan.

e-mail: fishii@my-pharm.ac.jp



membrane) between the anode and cathode, acidic electrolyzed water is obtained on the anode side and alkaline electrolyzed water on the cathode side (4,5). Acidic electrolyzed water shows pH 2-3. Its oxidation-reduction potential (ORP) is more than 1,100 mV, and its active chlorine content (ACC) is 10-90 ppm. Acidic electrolyzed water with these characteristics is widely used as sterilizing/disinfecting agents or deodorants, and is particularly used in the food industry due to its high-level safety (5).

Alkaline electrolyzed water shows pH 10-13 and ORP -800 - -900 mV (5), and is used mainly for the cleaning of industrial products due to its cleansing and antioxidative effects (6).

In the dental field, recent studies have shown the disinfecting and antibacterial effects of acidic electrolyzed water on dental bacteria, particularly pathogenic bacteria causing periodontal disease (7,8). There have also been studies on the use of alkaline electrolyzed water in the medical field (9,10).

Electrolytic reduction ion water (ERI) S-100<sup>®</sup> as a new specific water is produced by the electrolysis of an aqueous solution containing electrolytes using a specific electrolysis cell. Physically, ERI S-100<sup>®</sup> contains an excessive amount of electrons, and has effects such as cleaning, disinfection, antioxidation, and emulsification due to its specific alkaline property and negative ions (6,11,12). In the medical field, healing effects on burns have also been reported (13,14).

In this patient with atopic dermatitis accompanied by infection, in addition to treatment with oral drugs, topical agents, and injections, adjunctive therapy with acidic electrolyzed water with sterilizing effects and ERI lotion with skin care effects was performed, and favorable results were obtained.

## 2. Materials and Methods

### 2.1. Materials

Acidic electrolyzed water and ERI lotion (S-100<sup>®</sup>, 94.9%; glycerin, 3%; ascorbic acid, 2%; hyaluronic acid, 0.1%) manufactured by A.I. System Products Corp. was used. As the kampo preparation, we used Ourengedokutou<sup>®</sup> manufactured by Tsumura & Corp., Tokyo, Japan. For the steroid/antihistamine combination tablet, Emperacin<sup>®</sup> tablets (containing betamethasone *d*-chlorpheniramine maleate) manufactured by Sawai Pharmaceutical Co., Ltd., Osaka, Japan, was used. As the steroid/antibiotic combination ointment, Dexan-VG<sup>®</sup> 0.12% ointment (containing betamethasone valerate and gentamicin sulfate) manufactured by Fuji Pharma Co., Ltd., Tokyo, Japan, was employed. The vitamin A/E ointment was Juvela<sup>®</sup> (containing tocopherol and vitamin A oil) manufactured by Eisai Co., Ltd., Tokyo, Japan. For the

allergosis therapeutic drug, Histaglobin<sup>®</sup> subcutaneous injection manufactured by Nippon Zoki Pharmaceutical Co., Ltd., Osaka, Japan, was used.

### 2.2. Methods

Ourengedokutou<sup>®</sup> was administered at a daily dose of 7.5 g 3 times/day (before every meal or between meals), and Emperacin<sup>®</sup> (2 tablets at a time) was administered twice/day (after breakfast and supper). An appropriate amount of acidic electrolyzed water was applied to the affected areas twice daily, which was followed by the application of appropriate amounts of ERI lotion and a mixture of equal amounts of Dexan-VG<sup>®</sup> and Juvela<sup>®</sup> ointments. A subcutaneous Histaglobin<sup>®</sup> injection (1 vial/injection) was administered 1 week after the initiation of treatment and, subsequently, at 1-week intervals (total, 8 times).

## 3. Results

A female in her late 20s was diagnosed with systemic atopic dermatitis in another hospital 5 years earlier, and treated by steroid ointment application to affected areas and oral steroid administration. She visited our hospital due to the aggravation of dermatitis symptoms over the entire face from 1 week before the visit. Lesions were present over the face, chest, neck, and bilateral upper limbs, and, in particular, facial dermatitis was extensive. A diagnosis of systemic atopic dermatitis complicated by infection was made.

As oral drugs, a herbal medicine and steroid/antihistamine combination tablet were used. As topical drugs, an steroid/antibiotic combination ointment and vitamin E/A ointment were applied. In addition, subcutaneous Histaglobin<sup>®</sup> injections for the treatment of allergic disease were given, and acidic electrolyzed water and ERI lotion were topically applied for the sterilization of the skin surface and skin care. The treatment course is shown in Figure 1. Figures 1A-1D show photographs of the frontal face, right side of the face, left side of the face, and posterior neck, respectively, before treatment.

Compared with the pre-treatment state, redness and swelling decreased 1 week after the initiation of treatment (Figures 1E-1H). A subcutaneous Histaglobin<sup>®</sup> injection for the treatment of allergic disease was given at 1-week intervals. The course from 1 to 3 months after the initiation of treatment is shown in Figure 2. Swelling decreased 1 month after the initiation of treatment, but redness remained (Figures 2A-2C). Redness decreased after 1.5 months, showing a favorable course (Figures 2D-2F). Three months after the initiation of treatment, although slight redness was observed, the skin color was almost normal (Figures 2G-2I).



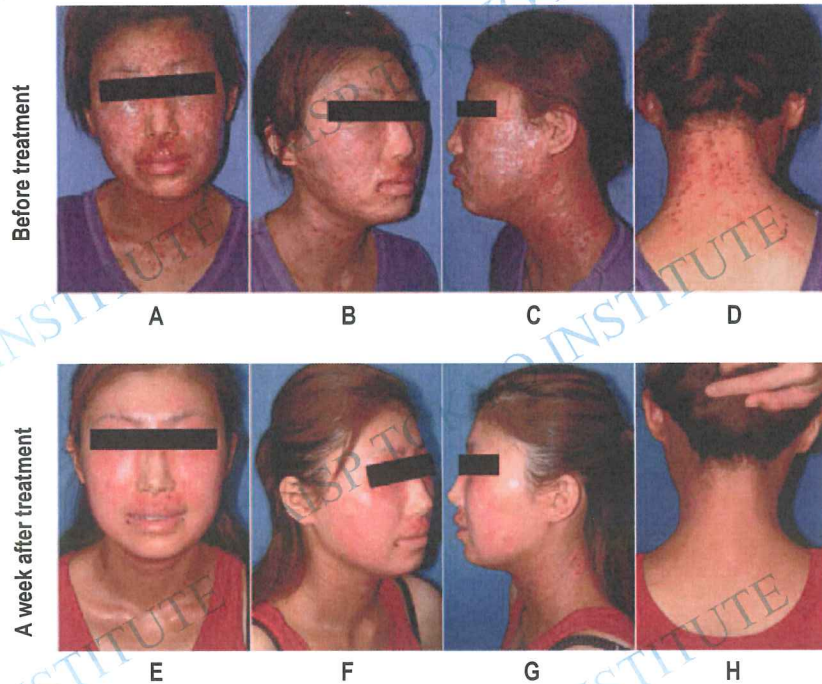
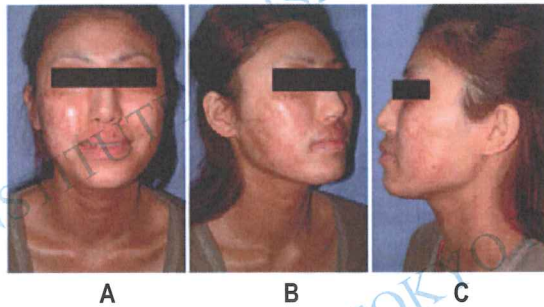
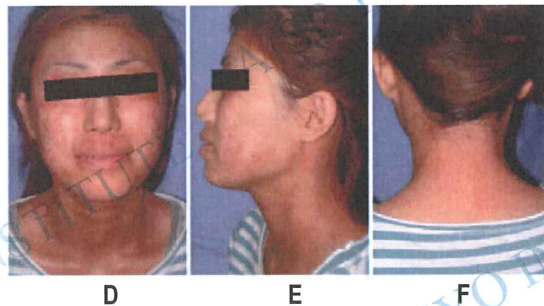
Figure 1. A case involving treatment of the facial surface and neck with ERI lotion, steroid/antibiotic combination ointment and vitamin E/A ointment. (A)-(D): Before treatment; (E)-(H): 1 week after treatment. (A), Front side; (B), Right side; (C), Left side; (D), Rear side; (E), Front side; (F), Right side; (G), Left side; (H), Rear side.

1 month  
After treatment



1.5 months  
After treatment



3 months  
After treatment

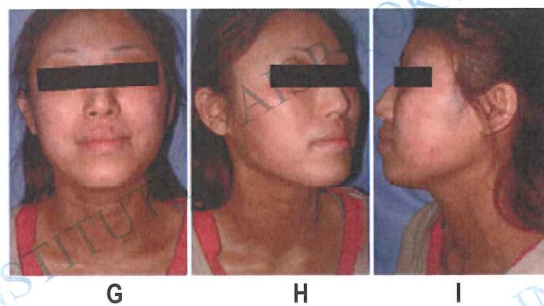

Figure 2. A case involving treatment of the facial surface and neck with ERI lotion, steroid/antibiotic combination ointment and vitamin E/A ointment. (A)-(C): 1 month after treatment; (D)-(F): 1.5 months after treatment; (G)-(I): 3 months after treatment. (A), Front side; (B), Right side; (C), Left side; (D), Front side; (E), Left side; (F), Rear side; (G), Front side; (H), Right side; (I), Left side.



#### 4. Discussion

Atopic differential tests of the patient's blood for single allergens revealed a class 6 IgE RAST score for Dermatophagoides pteronyssinus, cat skin debris, and dog skin debris, class 5 score for house dust 1, and a class 3 score for Japanese cedar. Therefore, she was informed of these allergens and given instructions for their elimination as adjunctive therapy.

She was initially treated by the application of an appropriate amount of acidic electrolyzed water to the affected areas for the sterilization and disinfection of skin surface bacteria, followed by the application of a steroid/antibiotic combination ointment. The Guidelines for Management of Atopic Dermatitis (1) recommend that a very strong or higher class topical steroid should be used first to improve eruptions, which is subsequently changed to a tacrolimus ointment with immunosuppressive effects. A study showed no increase in the incidence of skin infection using tacrolimus ointments (15), but others have reported an increase in the incidence of herpes simplex virus infection in the face and neck (16,17) using these ointments. In this patient, since severe infection was present in addition to atopic dermatitis, we did not use tacrolimus ointments with immunosuppressive effects but employed a strong class topical steroid containing an antibiotic.

In addition, to improve dryness, compensate for the decrease in barrier function, and prevent the relapse of inflammation due to scratching, skin care was performed with ERI lotion containing glycerin and hyaluronic acid with moisturizing effects, and vitamin E/A ointment with skin microcirculation-activating and skin protection effects.

Since dermatitis and infection symptoms improved 1 week after the initiation of treatment compared with the pre-treatment state, she was instructed to gradually reduce the dose of the topical steroid while paying attention to the possible relapse of inflammation, and similar treatment was continued (Figures 1A-1H).

Since the condition became stable after 1 month, the frequency of application of the topical steroid was gradually decreased while the application of the acidic electrolyzed water, ERI lotion, and vitamin E/A ointment was continued (Figures 2A-2C).

A marked improvement of symptoms was observed after 3 months compared with the pre-treatment state, suggesting that not only topical steroid application but also adjunctive skin care by the application of the acidic electrolyzed water, ERI lotion, and vitamin E/A ointment was also effective.

In this study, we used ERI lotion, expecting its effects on atopic dermatitis because its effects on burns have been suggested (13,14). Atopic dermatitis tends to induce bacterial/fungal/viral skin infection. Therefore, the application of ERI lotion as alkaline electrolyzed water, as well as acidic electrolyzed water,

is effective for the prevention of these infections. Povidone iodine and alcohol disinfectants have a skin-damaging action, whereas ERI lotion is less of a skin irritant, has emulsification effects, and does not contain surfactants used for the preparation of emulsions. Topical steroids are used twice/day in principle, and their long-term use runs the risk of severe adverse effects such as glaucoma due to increased ocular pressure or posterior capsule opacification. If dermatitis does not relapse, it is important to decrease the amount and frequency of topical steroid application according to the symptoms, and change topical steroid therapy to maintenance therapy with acidic electrolyzed water, ERI lotion, and vitamin E/A ointment.

#### 5. Conclusion

In this patient, skin redness and swelling markedly improved, and healing to an almost normal state without pigmented scars was observed. These results suggest the effectiveness of complex therapy consisting of a herbal medicine and steroid/antihistamine combination tablet as oral drugs, a steroid/antibiotic combination ointment and vitamin E/A ointment as topical drugs, subcutaneous injections for the treatment of allergic disease, acidic electrolyzed water, and ERI lotion for treating atopic dermatitis complicated by infection.

#### References

1. Saeki H, Furue M, Furukawa F, Hide M, Ohtsuki M, Katayama I, Sasaki R, Suto H, Takehara K; COMMITTEE for GUIDELINES for the MANAGEMENT of ATOPIC DERMATITIS of JAPANESE DERMATOLOGICAL ASSOCIATION. Guidelines for management of atopic dermatitis. *J Dermatol.* 2009; 36:563-577.
2. Furue M, Saeki H, Furukawa F, Hide M, Ohtsuki M, Katayama I, Sasaki R, Suto H, Takehara K. Guidelines for management of atopic dermatitis. *Jpn J Dermatol.* 2009; 119:1515-1534.
3. Japanese FK506 Ointment Study Group. Clinical guidance for treatment of patients with atopic dermatitis by tacrolimus ointment 0.1% and 0.03%. *Jpn J Clinical Dermatol.* 2003; 57:1217-1234.
4. Guide for the electrolyzed reduced water. Functional Water Foundation. 2002; pp. 261-266.
5. Hricova D, Stephan R, Zweifel C. Electrolyzed water and its application in the food industry. *J Food Prot.* 2008; 71:1934-1947.
6. Okajima M. Proceedings of Japanese society for Applied Research in Negative Ion. 2002.
7. Ozawa H, Arai T. Guideline of the electrolyzed functional water in the dentistry. *J Tokyo Dental Association.* 2009; 57:4-10.
8. Kato T, Yamanaka A, Yamada K, Kimizuka R, Ishihara K, Okuda K. Evaluation of antimicrobial effect of electrolyzed oxidizing water (EO water) using oral microbial biofilm models. *Bacterial Adherence Biofilm.* 2006; 20:116-121.
9. Huang KC, Yang CC, Lee KT, Chien CT. Reduced

- hemodialysis-induced oxidative stress in end-stage renal disease patients by electrolyzed reduced water. *Kidney Int.* 2003; 64:704-714.
10. Huang KC, Yang CC, Hsu SP, Lee KT, Liu HW, Morisawa S, Otsubo K, Chien CT. Electrolyzed-reduced water reduced hemodialysis-induced erythrocyte impairment in end-stage renal disease patients. *Kidney Int.* 2006; 70:391-398.
  11. Konomatu A, Sugibayashi K, Okajima M, Ishii F. Preparation and stability of surfactant free emulsions using electrolyzed deoxidized and ionized water. *Material Tech.* 2003; 21:273-285.
  12. Kitagawa T, Okajima M, Shimokawa K, Ishii F. Physicochemical properties of magnesium aluminum silicates (smectites) gels prepared by electrolytic-reduction ion water. (1): Rheological properties. *Material Tech.* 2008; 26:50-54.
  13. Okajima M, Shimokawa K, Ishii F. The healing effect of electrolytic-reduction ion water on burn wounds. *BioSci Trends.* 2010; 4:31-36.
  14. Shu T, Okajima M, Shimokawa K, Ishii F. The treatment effect of the burn wound healing by electrolytic-reduction ion water lotion combination therapy. Part 2: Two degree burn of forearm to the dorsum of the hand. *BioSci Trends.* 2010; 4:213-217.
  15. Fleischer AB Jr, Ling M, Eichenfield L, Satoi Y, Jaracz E, Rico MJ, Maher RM; Tacrolimus Ointment Study Group. Tacrolimus ointment for the treatment of atopic dermatitis is not associated with an increase in cutaneous infections. *J Am Acad Dermatol.* 2002; 47:562-570.
  16. Furue M, Terao H, Rikihisa W, Urabe K, Kinukawa N, Nose Y, Koga T. Clinical dose and adverse effects of topical steroids in daily management of atopic dermatitis. *Br J Dermatol.* 2003; 148:128-133.
  17. Furue M, Terao H, Moroi Y, Koga T, Kubota Y, Nakayama J, Furukawa F, Tanaka Y, Katayama I, Kinukawa N, Nose Y, Urabe K. Dosage and adverse effects of topical tacrolimus and steroids in daily management of atopic dermatitis. *J Dermatol.* 2004; 31:277-283.

*(Received October 25, 2010; Accepted December 17, 2010)*