

Brief Report

The treatment effect of the burn wound healing by electrolytic-reduction ion water lotion combination therapy. Part 2: Two degree burn of forearm to the dorsum of the hand

Tetsuo Shu^{1,*}, Masahiro Okajima², Yuko Wada², Ken-ichi Shimokawa², Fumiyoshi Ishii^{2,**}

¹ Daikanyama Clinic of Cosmetic Surgery, Shibuya-ku, Tokyo, Japan;

² Department of Pharmaceutical Sciences, Meiji Pharmaceutical University, Tokyo, Japan.

Summary

Patient 1: A 1-year-and-3-month-old boy suffered a burn injury extending from the left forearm to hand due to boiling water. An extensive skin defect from the left forearm to the dorsum of the hand was observed, and an IIb-III degree burn was diagnosed. Treatment of the burn was started with the application of electrolytic-reduction ion water (ERI) lotion, antibiotic/steroid combination ointment, and vitamin A/E ointment with wrap therapy. Two days after the initiation of therapy, redness and swelling were still observed despite a slight decrease in swelling. After 21 days, skin redness decreased, and there was no functional impairment. After 74 days, the skin color was almost normal, and no functional impairment was observed, showing a favorable course.

Patient 2: An 8.5-month-old girl suffered a burn injury extending from the fingers to dorsum of the right hand and right wrist due to boiling water. There was an extensive skin defect accompanied by bulla formation extending from the fingers and dorsum of the right hand. An II-degree burn was diagnosed. Treatment of the burn was started treatment similar to the Patient 1. Bulla decreased, but redness and swelling were still present 2-8 days after the initiation of therapy. After 16-25 days, both skin redness and swelling decreased. After 30 days, the epithelialization of the dorsum of the hand had almost completed. After 60 days, the skin color was nearly normal, and there was no functional impairment, showing a favorable course.

In these patients, burn wounds completely healed without hypertrophic or keloid scar formation or pigmentation. These results suggest that extensive II-III burns can be adequately treated by this topical therapy.

Keywords: Electrolytic-reduction ion water (ERI), burn wound, moist wound healing, conservative treatment, wrap therapy

1. Introduction

Major surgical primary emergency disorders in children include injuries, burns, inflammatory diseases, and the accidental ingestion of foreign bodies (1,2). Among them, the number of burn cases is high, and burns in infants are often severe. In

the treatment of II and III burns, local therapy with disinfectants and ointments containing steroids or antibiotics was conventionally performed to inhibit infection of the wound surface. However, in recent years, this conventional therapy has been gradually changed to occlusive dressing therapy with wound dressings (such as polyurethane films, hydrocolloid, polyether foam, and hydro-gel) that maintains the moist environment in the burn area and optimizes the repair function of the body (3-5). In addition, studies have shown that plastic films for food wrapping (wrap films) can be inexpensive materials appropriate for dressing, and therapy using wrap films (wrap therapy) is an effective burn treatment method (6,7).

*Dr. Tetsuo Shu passed away.

**Address correspondence to:

Dr. Fumiyoshi Ishii, Department of Pharmaceutical Sciences, Meiji Pharmaceutical University, 2-522-1 Noshio, Kiyose, Tokyo 204-8588, Japan.
e-mail: fishii@my-pharm.ac.jp

Electrolytic-reduction ion water (ERI) is water physically abundant in extra electrons produced by the electrolysis of natural water. Due to its special alkaline property and negative ions, ERI shows various favorable effects such as cleaning, disinfectant, antioxidant, and emulsifying effects (8-11).

In this study, in patients 1 and 2, wrap therapy as conservative treatment with an ERI lotion, antibiotic/steroid combination ointment, and vitamin A/E ointment was performed, and favorable results could be obtained.

2. Materials and Methods

2.1. Materials

ERI lotion manufactured by A.I. System Products Co., Aichi, Japan (S-100, 94.9%; glycerin, 3%; ascorbic acid, 2%; hyaluronic acid, 0.1%) was used. As antibiotic/steroid combination ointments, Hysetin-P[®] ointment (containing chloramphenicol, fradiomycin sulfate, and prednisolone) and Dexan-G[®] ointment (containing betamethasone valerate and gentamicin sulfate) manufactured by Fuji Pharma Co., Ltd. (Shizuoka, Japan) were used. As a vitamin A/E ointment, Juvela[®] ointment (containing tocopherol and vitamin A oil) manufactured by Eisai Co., Ltd. (Tokyo, Japan) was used.

2.2. Methods

The burn was treated by the application of ERI lotion, antibiotics/steroid combination ointment (Hysetin-P or Dexan-G), and vitamin A/E ointment (Juvela) to the burn area 3 times/day combined with wrap therapy, *i.e.*, wrapping the injury site with a thin plastic film to prevent drying (12).

3. Results and Discussion

3.1. Patient 1

A male aged 1 year and 3 months sustained burn injury to the dorsum of the hand and was treated on an outpatient basis in another hospital. Four days after injury, he was taken to our hospital. There was an extensive skin defect over the entire dorsum of the hand. A diagnosis of a IIb-III burn was made. The treatment course from the first consultation day to 130 days after the initiation of treatment is shown in Figure 1.

Figure 1A shows the state on the first consultation day. Marked redness and swelling of the fingers and dorsum of the left hand and the left wrist were observed. The central area of the dorsum of the hand was whitish. The skin was detached from the lower 1/2 area of the fingers to the entire dorsum of the hand. Therefore, an ERI lotion, antibiotic/steroid combination ointment (Hysetin-P ointment), and vitamin A/E ointment

(Juvela ointment) were applied to the burn area, and wrap therapy was initiated. Figure 1B shows the state 2 days after the initiation of therapy. Redness and swelling were still observed despite a slight reduction in swelling. After 3-6 days, redness and swelling were still present (Figures 1C-1E). After 7 days, Hysetin-P ointment as an antibiotic/steroid ointment was changed to Dexan-G ointment, and burn treatment was continued employing a similar method (Figure 1F). Figure 1G shows the state after 10 days. Redness and swelling persisted despite a slight reduction in redness. Figure 1H shows the state after 16 days. Skin redness further reduced, and swelling decreased. Figures 1I and 1J show the states after 17 and 21 days, respectively. Skin redness further decreased, and there was no functional impairment. After 32 days, the epithelialization of the dorsum of the hand was completed (Figure 1K). Figures 1L and 1M show the states after 44 and 74 days, respectively. Despite slight skin redness, no functional impairment was observed, showing a favorable course. Redness was negligible 98 days after the initiation of therapy (Figure 1N). After 130 days, there was neither scar formation nor pigmentation, and the skin color was normal in appearance. Therefore, the burn wound was considered to have completely healed (Figure 1O).

3.2. Patient 2

The treatment course from the first consultation day to 111 days after the initiation of treatment is shown in Figure 2. On the first consultation day, marked redness and swelling accompanied by bullae were observed in the fingers-dorsum of the right hand and right wrist. In particular, the degree of the burn was IIa-IIb in the right thumb, index finger, middle finger, and the central area of the dorsum of the hand (Figure 2A). Therefore, an ERI lotion, antibiotic/steroid combination ointment (Hysetin-P ointment), and vitamin A/E ointment (Juvela ointment) were applied to the burn area, and wrap therapy was initiated. After 2-8 days, bullae decreased, but redness and swelling were still present (Figures 2B-2G). Therefore, Hysetin-P ointment as an antibiotic/steroid combination ointment was changed to Dexan-G ointment, and burn treatment was continued employing a similar method (Figure 2H). After 13 days, redness and swelling were present despite a slight decrease in redness (Figure 2I). After 16-25 days, both skin redness and swelling decreased (Figures 2J-2L). After 30 days, the epithelialization of the dorsum of the hand was nearly completed (Figure 2M). After 60 days, the skin color was almost normal, and no functional impairment was observed, showing a favorable course (Figure 2N). After 111 days, there was a slight scar but no pigmentation, and the skin color was normal in appearance. Therefore, the burn

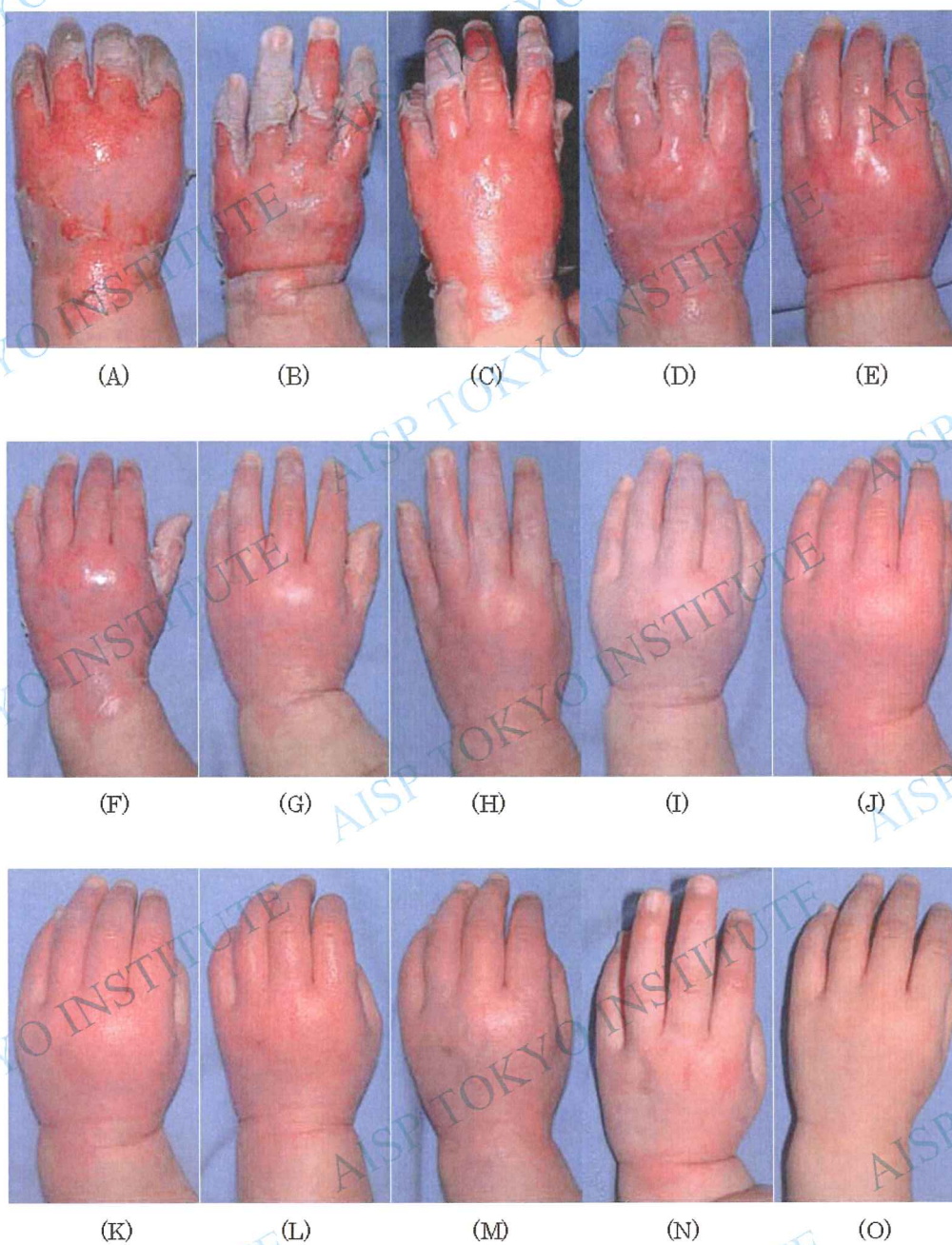

Figure 1. Patient 1: A case involving treatment of the dorsum of the left hand with ERI lotion, antibiotic/steroid combination ointment, and vitamin A/E ointment employing wrap therapy. (A) Before treatment. (B) 2nd day after treatment. (C) 3rd day after treatment. (D) 5th day after treatment. (E) 6th day after treatment. (F) 7th day after treatment. (G) 10th day after treatment. (H) 16th day after treatment. (I) 17th day after treatment. (J) 21st day after treatment. (K) 32nd day after treatment. (L) 44th day after treatment. (M) 74th day after treatment. (N) 98th day after treatment. (O) 130th day after treatment.

wound was considered to have completely healed (Figure 2O).

Burn injuries often require surgical skin grafting depending on their depth in addition to conventional topical therapy. Our patients had II-III burns. However, since their parents hoped for treatment on an outpatient basis, wrap therapy as conservative treatment with an ERI lotion, antibiotic/steroid combination ointment, and

vitamin A/E ointment was performed. In these patients, Hysetin-P ointment was changed to Dexan-G ointment 7-9 days after the initiation of therapy. This was because ointments showing the more marked anti-inflammatory activity of topical steroids were considered to be more effective.

In both patients, the tissue repair course for burn healing smoothly advanced, resulting in complete healing without hypertrophic or keloid scar formation

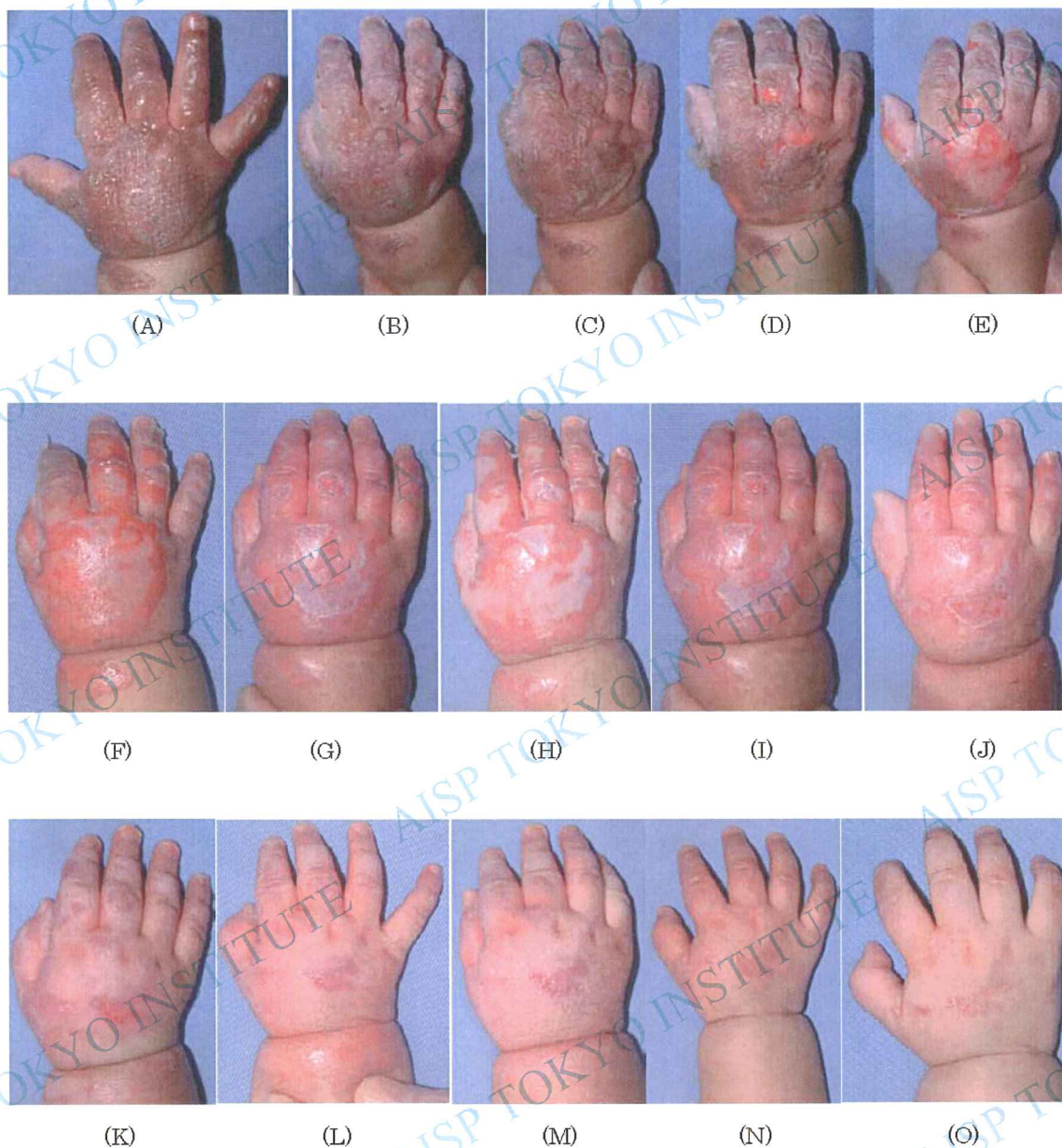


Figure 2. Patient 2: A case involving the treatment of all fingers and the dorsum of the right hand with ERI lotion, antibiotic/steroid combination ointment, and vitamin A/E ointment employing wrap therapy. (A) Before treatment. (B) 2nd day after treatment. (C) 3rd day after treatment. (D) 4th day after treatment. (E) 5th day after treatment. (F) 6th day after treatment. (G) 8th day after treatment. (H) 9th day after treatment. (I) 13th day after treatment. (J) 16th day after treatment. (K) 20th day after treatment. (L) 25th day after treatment. (M) 30th day after treatment. (N) 60th day after treatment. (O) 111th day after treatment.

or pigmentation. These results suggest that extensive II-III burns can be adequately treated by topical therapy with an ERI lotion, antibiotic/steroid combination ointment, and vitamin A/E ointment.

References

- Hettiaratchy S, Dziewulski P. ABC of burns: Pathophysiology and types of burns. *BMJ*. 2004; 328:1427-1429.
- Koike Y, Honda S, Tsuda I, Nakagawa T, Ito Y, Une Y, Onishi S, Imai A. Analysis of surgical primary emergency cases in infants. *Journal Clinical Pediatrics (Sapporo)*. 2003; 51:19-22. (in Japanese)
- Kujath P, Michelsen A. Wounds – From physiology to wound dressing. *Dtsch Arztebl Int*. 2008; 105:239-248.
- Brett DW. A review of moisture-control dressings in wound care. *J Wound Ostomy Continence Nurs*. 2006; 33 (Suppl 6):S3-S8.
- Ogawa Y. Wound dressing. *The Japanese Journal of Acute Medicine*. 2003; 27:74-76. (in Japanese)
- Natui M. Therapeutic management of problematic superficial wounds: A patients-centered approach. *J*

- Wound Care. 2003; 12:63-66.
7. Kubota T, Kaneko W. Local treatment for partial thickness burns of infants and children, using thin plastic film for food packaging. Japanese Society of Emergency Pediatrics. 2007; 6:177-180. (in Japanese)
 8. Okajima M. Proceeding of Japanese society for applied research in negative ion. 2002.
 9. Konomatu A, Sugibayashi K, Okajima M, Ishii F. Preparation and stability of surfactant free emulsions using electrolyzed deoxidized and ionized water. Mater Technol. 2003; 21:273-285.
 10. Takigawa T, Shimokawa K, Ishii F, Okajima M. Physicochemical properties of magnesium aluminum silicates (smectites) gels prepared by electrolyticreduction ion water. (1): Rheological properties. Mater Technol. 2008; 26:50-54.
 11. Shu T, Okajima M, Shimokawa K, Ishii F. The treatment effect of the burn wound healing by electrolyticreduction ion water lotion. Biosci Trends. 2010; 4:1-3.
 12. Okajima M, Shimokawa K, Ishii F. The healing effect of electrolytic-reduction ion water on burn wounds. Biosci Trends. 2010; 4:31-36.

(Received June 12, 2010; Revised July 20, 2010; Accepted August 8, 2010)